

S.M.O.E. Information Bulletin

Quarterly Publication

Registration Court of Milan
dated April 2001.

Subscription delivery postage
Advertising not above 70%.

Editorial Office: S.M.O.E.

Telex -
Tel. 020 -
Fax 0272022

Reproduction of copyright material is
forbidden and criminally prosecuted
dated April 22, 2001.



S.I.M.O.E.

**THE ITALIAN SOCIETY OF COSMETIC
PHYSICIANS AND SURGEONS
(NO PROFIT)**

Information Bulletin
June 2006

Contents:

Foreword	3
Starting from scratch	3
Submental Nd:YAG Laser-Assisted Liposuction	5
Combined use of poly-lactic acid and the method in facial aging	12
Psycho-dynamic assessment in Aesthetic Medicine and Surgery	14
Selected Abstracts in Aesthetic Medicine and Surgery	15
Meetings and Courses	23
Index	27

Submental Nd:YAG Laser-Assisted Liposuction

*Dr. Alberto Goldman, ~~BGS~~ BGS, FRCR
Member Scientific Committee, SIMOE*

Background and Objectives: Liposuction of the neck is currently one of the most common cosmetic surgical procedures. In the present study, the author describes his experience with neck and jowl laser-assisted liposuction.

Study Design/Materials and Methods: In this procedure, submental lipodystrophy is treated with an Nd:YAG laser, at a 1,064 nm wavelength. Over a 5-year-period, 82 subjects were treated using 6-W power, 40-Hz frequency, 150-mJ energy, and 100-microsecond pulse width parameters. Histology was performed on fatty tissue samples.

Results: Submental laser-assisted liposuction resulted in significant cosmetic improvement. Histology revealed a rupture of the adipocyte membrane as well as collagen coagulation and channels along the fatty tissue. Additionally, small blood vessels were coagulated. An adequate skin contraction was observed with an improvement of the cervicofacial region.

Conclusions: The Nd:YAG laser is a useful tool for the treatment of local lipodystrophy. The laser proved to be effective for cellular lysis and collagen neoformation.

Lasers Surg. Med. 38:181–184, 2006.

© 2006 Wiley-Liss, Inc.

INTRODUCTION

Accumulation of submental fat causes the cervicofacial concavity to decrease, eventually approaching a flat angle or convexity. This may be more apparent as the skin loses elasticity and begins to hang.

Submental liposuction is not only a procedure with low-risk but also a relatively inexpensive one. This treatment can offer dramatic changes to the appearance of the neck and mandibular border. With recent technical advances, the results achieved with this surgical treatment have become safer and more effective.

Liposuction has become increasingly popular over the last decade and is now among the most popular body sculpting procedures. This increasing popularity is associated with the evolution of techniques and equipment for fat removal and body reshaping.

Besides the traditional suction-assisted lipoplasty, other options include ultrasound-assisted and external ultrasound-assisted liposuction, power-assisted liposuction, laser lipolysis as well as low-level laser-assisted liposculpture. The efforts in the search for alternatives and new tools aim mainly at reducing downtime, decreasing operator effort for the surgeon and assistant, reducing bleeding, promoting skin tightening, and facilitating treatment of fibrous or reoperative areas. © 2006 Wiley-Liss, Inc.

Recently, lasers have been adapted for the treatment of localized fat. The laser-fat interaction was initially described by Apfelberg [1–3] in 1992.

Publications by Blugerman, Schavelzon, and Goldman [4–9] demonstrated their experience with lasers used directly on adipose tissue in a procedure called laserlipolysis. Later, Badin [10,11] published his experience with laserlipolysis, highlighting the important tissue retraction obtained with this technique. Neira [12] analyzed the probable formation of a pore on the adipocyte membrane after the action of an external laser. However, the result was questioned and non-reproducible in a publication by Brown [13]. In a recent study, Ichikawa [14] showed the histological evaluation in subjects and laboratory animals treated with laserlipolysis.

“Background and Objectives: Liposuction of the neck is currently one of the most common cosmetic surgical procedures. In the present study, the author describes his experience with neck and jowl laser-assisted liposuction.”

The mechanism of action of laserlipolysis is selective photothermia. In this process, laser-light energy is converted into heat energy when absorbed by fat. Conducted by a flexible fiber optic delivered through a cannula, the laser energy is transmitted to the adipocytes, which absorb the energy and rupture.

The action time of the laser varies according to the area to be treated and tissue resistance. All subjects suitable for a traditional liposuction method can also be treated with laserlipolysis.

MATERIALS AND METHODS

A total of 82 consecutive subjects who underwent the submental laserlipolysis procedure between March 1999 and November 2004, at Clínica Goldman de Cirurgia Plástica, in Porto Alegre, Brazil, were included in the study. All underwent pre-operative assessment to determine their general medical condition. None were obese and all were non-smoking and in normal or well-controlled health. All subjects provided informed consent.

The procedure was recommended for patients with neck lipodistrophy, without strong vertical platysmal bands, and without significant skin laxity.

Dr. Alberto Goldman is a senior member of the Brazilian Society of Plastic Surgery, member of the International Society of Aesthetic Plastic Surgery, member of the Brazilian Society of Laser in Medicine and Surgery, and director of Clínica Goldman of Plastic Surgery.

*Correspondence to: Dr. Alberto Goldman, Avenue Augusto Meyer 163 conj. 1203, Porto Alegre, RS 90550-110, Brazil.

E-mail: alberto@goldman.com.br

Accepted 29 September 2005

Published online 1 February 2006 in Wiley InterScience

(www.interscience.wiley.com).

DOI 10.1002/Ism.20270

TABLE 1. Demographics of Subjects Undergoing Submental Laserlipolysis

Number of subjects	82
Average age (years)	35.53 (18–61)
Males	4 (5%)
Females	78 (95%)

The procedures were performed after subcutaneous infiltration of a solution containing 20 cc of 2% lidocaine with vasoconstrictor and 20 to 30 cc of warm saline solution.

The procedure was initiated following a 20-minute delay, allowing for diffusion of infiltrate and appropriate vasoconstriction.

Of the 82 subjects, 4 (5%) were men, and 78 (95%) were women. Ages ranged from 18 to 61 years, with an average of 35.53 years (Table 1).

All procedures were performed using local anesthesia or local anesthesia assisted by an anesthesiologist. Histological studies were performed in some subjects, focusing on the effects of the laser on the vessels, fat, and dermis while using different colorations such as Orcein and Hematoxylin eosin. Biopsies were obtained immediately after laser irradiation and 40 days following the procedure, with the consent of the patient.

Laser

A 1,064 nm Nd:YAG laser at 40-Hz frequency, 150-mJ energy, 6-W power, and 100-microsecond pulse duration was used (Deka, Florence, Italy). In this procedure, the laser energy is conducted to the adipose tissue through a 300-micron fiber optic, delivered through a 1 mm diameter stainless steel micro-cannula of variable length. The distal portion of the fiber optic is extended approximately 2 mm beyond the distal end of the cannula (Fig. 1). For visualization purposes, a He:Ne laser source is combined into the beam path. The association of the 1,064 nm laser with a He:Ne source allows precise visualization of the region where the energy is acting, due to cutaneous transillumination. A 1 mm incision is enough to introduce the cannula, which is then moved in the fat tissue at various depths, including the subdermal layer, similarly to a superficial liposuction.

When in contact with the previously infiltrated fatty tissue, the light energy produced by the laser is absorbed and converted to heat, thereby expanding the adipocyte contents and rupturing the cell membrane.

Thus, through the phenomenon of photohyperthermia, cellular rupture is produced.




Fig. 1. One-millimeter cannula containing fiber optic extended approximately 2 mm from the distal end and emitting

A photoacoustic effect may also play a role in cellular lysis, due to the rapid absorption by and heating of the cell.

This laser treatment is delivered over a varying length of time, and total deposited energy goes according to the size of the treated area, and tissue resistance. In areas of fibrosis or previously treated zones, the treatment time is typically longer.

The equipment provides accumulated energy in joules, which can be used as a reference for treatment of similar areas in different subjects.

Depending on the volume of treated fat, an oily solution, the product of the cellular lysis, was removed using negative pressure of around 450 mm of Hg in conjunction with a suction cannula. Aspiration of laser lipolysis debris was only not performed in cases where the treated area contained very small volumes of fat or in subjects where the goal was to produce superficial relaxation for the purpose of tissue adjustment or cellulite attenuation.

Submental laser lipolysis was performed as an outpatient procedure and after the first post-operative day the patients gradually returned to their normal daily activities, usually with little discomfort. In some cases, a smooth compression was used for 1 week. On the second day, the patients initiated treatment with manual lymphatic drainage, external ultrasound, low-power external laser, and other physiotherapeutic cares.

Complications included two cases of asymmetry. No case of injury to the marginal mandibular nerve was observed in this series.

“Results: Submental laser-assisted liposuction resulted in significant cosmetic improvement. Histology revealed a rupture of the adipocyte membrane as well as collagen coagulation and channels along the fatty tissue. Additionally, small blood vessels were coagulated. An adequate skin contraction was observed with an improvement of the cervicofacial region”.

Subjects were treated in the outpatient setting and were discharged immediately after the procedure or a few hours following the procedure. The careful and judicious selection and preparation of subjects, as well as proper subject orientation, were essential for the success and safety of the procedure.

RESULTS AND HISTOLOGICAL STUDIES

The histological assessment was carried out on tissues removed from the subjects immediately following the procedure, and on biopsies taken approximately 40 days following the procedure. Significant findings following laserlipolysis included the coagulation of small blood vessels in the fatty tissue (Fig. 2), the rupture of adipocytes, the appearance of small channels produced by laser action (Fig. 3), reorganization of the reticular dermis (Fig. 4), and coagulation of collagen in the fat tissue (Fig. 5).

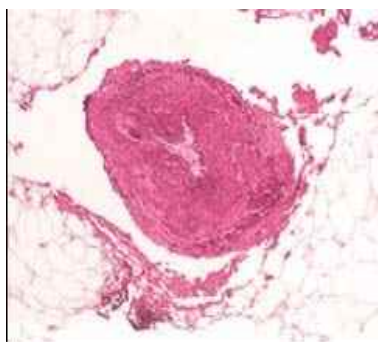


Fig. 2. Histology showing coagulation of small blood vessels in fat tissue by means of laser action (Orcein 32x).

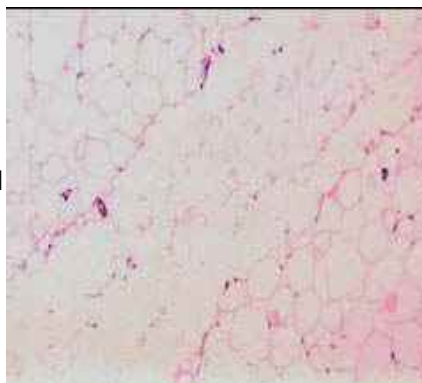


Fig. 3. Channel produced by Nd: YAG laser, showing the rupture of adipocytes and fragments of adipose cell membranes (Hematoxylin eosin 32 x).

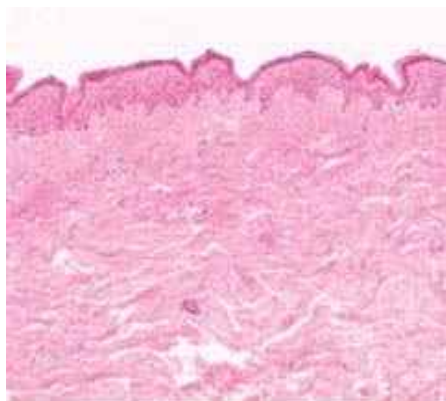


Fig. 4. Reorganization of reticular dermis. (Hematoxylin eosin 32 x).

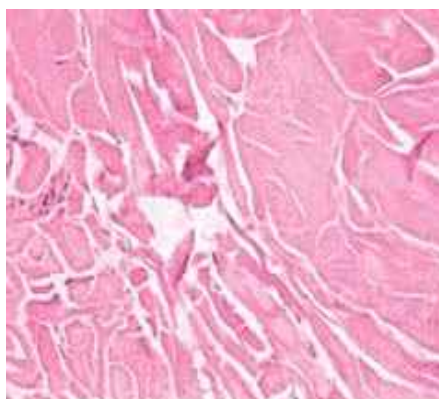


Fig. 5. Collagen coagulation (Hematoxylin eosin 100 x).

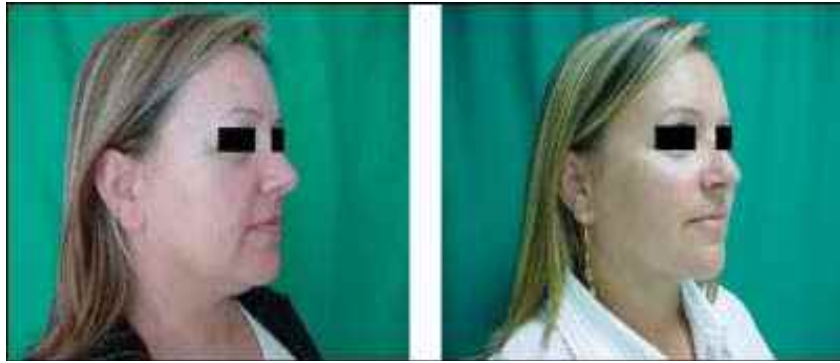

Fig. 6. A 40-year-old woman with submental lipodystrophy. **(Left)** Pre-operative views. **(Right)** Post-operative views after 7 months.

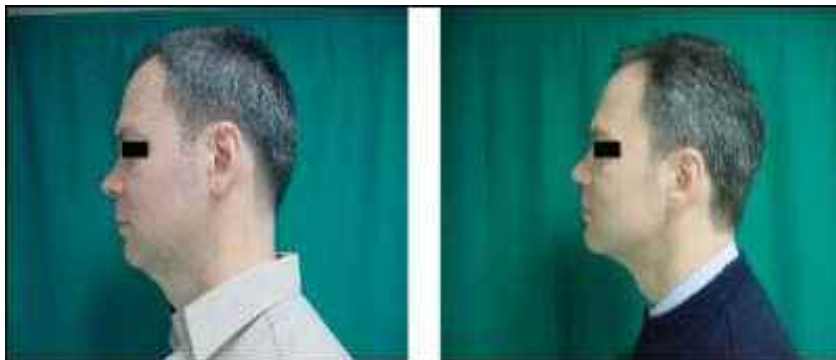

Fig. 7. A 43-year-old man. **Left:** Pre-operative view. **Right:** Post-operative view after 5 months.

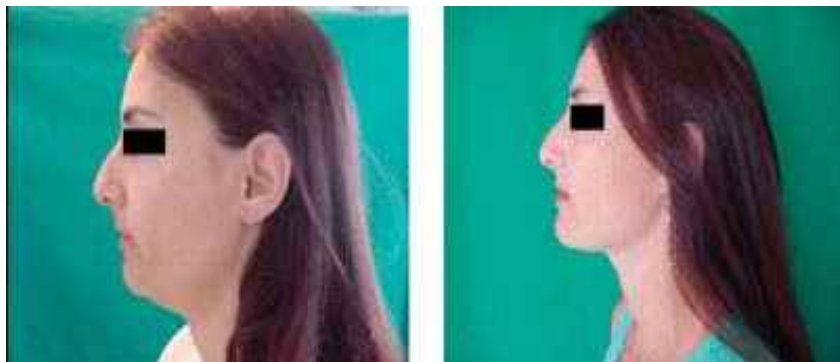

Fig. 8. A 36-year-old patient who underwent laser-assisted liposuction on the submental region. **Left:** Pre-operative views. **Right:** Post-operative views after 3 months.

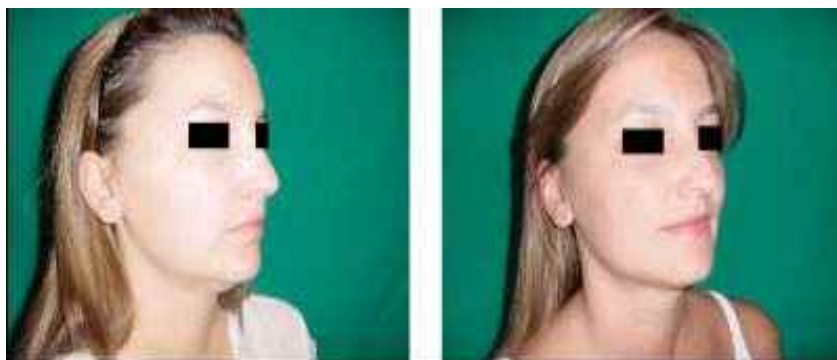

Fig. 9. A 31-year-old woman with submental lipodystrophy. **Left:** Pre-operative views. **Right:** Post-operative views after 7 months.

Although the final result obtained with laserlipolysis was similar to the author's experience with traditional liposuction methods, the histological findings suggest several positive benefits brought out by the use of the Nd:YAG laser (Figs. 6–9), which include skin retraction—due to collagen neoformation—and a reduction in transoperative and postoperative bleeding as well as in the population of adipocytes.

Complications were similar to those found with other lipoplasty methods and, in this study, there were no side effects directly related to the laser use.

DISCUSSION

The aim of this study was to analyze the effects of the direct Nd:YAG laser irradiation on fat tissue and the results of this procedure—laserlipolysis—in the submental region. There are few studies in the literature showing laser action on lipodistrophy. The techniques published to date using laser described both external and internal methods. This method of lipoplasty exhibited results similar to those from other traditional body sculpting methods previously used by the author. Internal laserlipolysis with 1,064 nm Nd:YAG laser has been proving to be a safe and effective method. The decrease in tissue trauma is likely to be associated with the laser-induced coagulation of small vessels in the fat tissue, the adequate infiltration of the anesthetic solution and the possibility of using smaller caliber cannulas. The treatment of areas where fat removal is difficult, as is the case of gynecomastia and previously operated areas, is facilitated by the small diameter of the microcannula containing the laser fiber.

The thermal action of the beam facilitates movement of the cannula, consequently entailing less effort and fatigue for the surgeon. The visualization of a reddish color from the He–Ne source, due to its transillumination through the skin, makes the procedure very precise, given that the surgeon knows exactly where the laser is acting.

The potential to use the laser for superficial treatment, as proposed by Bolivar [15], may represent another option for the treatment of cellulite, remodeling collagen, and smoothing the treated area.

Although it still represents a recent technical option, several authors have demonstrated similar results in histological evaluations, describing the effects of the Nd:YAG laser on adipocytes. The main findings are the rupture of the adipocyte cell membrane, the formation of channels, and the coagulation of the collagen. These factors may be responsible for the observed tissue retraction following the procedure.

Although some studies have failed to demonstrate the value of low-intensity laser acting transcutaneously, these findings cannot be applied to the technique described, which employs laser energies far in excess of those employed in low-level techniques.

The laser energy from the Nd:YAG used in this study acts directly in contact with the adipose cells, making it unnecessary to cross the skin barrier. Although several authors have corroborated the findings of this study, further clinical studies are still necessary in order to better define the value and limitations of the technique.

The histological findings and post-operative clinical outcomes of subjects who underwent laser lipolysis of the submental area, neck, and jowl have proven the safety and effectiveness of this procedure. Although the laser lipolysis using a Nd:YAG laser has been shown to be effective and safe in this series, further studies are necessary to improve and clarify the utility of this technique.

ACKNOWLEDGMENTS

The author thanks Dr. Diego Schavelzon and Dr. Guillermo Blugerman for their invaluable scientific collaboration.

“Conclusions:

The Nd:YAG laser is a useful tool for the treatment of local lipodistrophy. The laser proved to be effective for cellular lysis and collagen neoformation”.